

Carotid Sheath MCQ

It is a tube of deep fascia extending from base of the skull down to root of the neck,

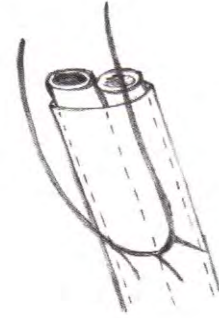
IT SURROUNDS THE:

MCQ

- 1) **Internal Jugular vein:** laterally.
- 2) **Common carotid & internal carotid a:** medially.
N.B: ext carotid is not surrounded by the sheath
- 3) **Vagus nerve:** behind the interval between the internal jugular vein & common carotid artery.

STRUCTURES EMBEDDED IN ITS WALLS:

- 1) **Sympathetic trunk:** embedded in posterior wall.
- 2) **Ansa Cervicalis & its roots:** embedded in the ant wall

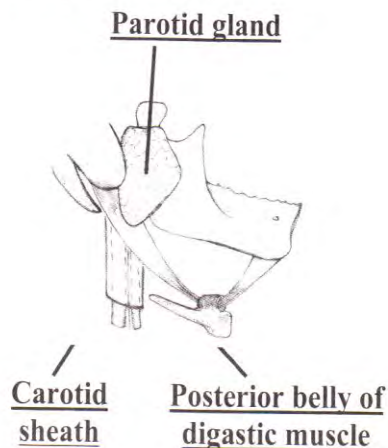
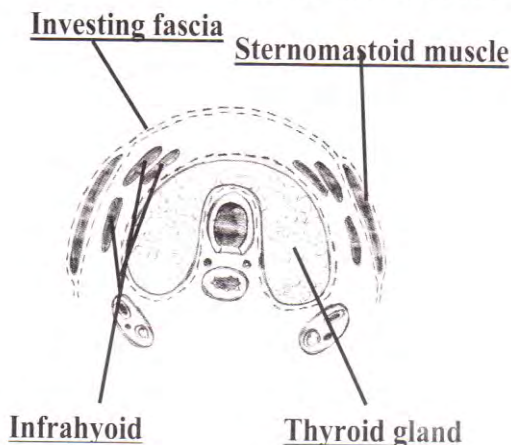


SUPERFICIAL RELATIONS:

- Below upper border of thyroid cartilage :
 - Thyroid gland.
 - Infrahyoid muscles (sternohyoid, sternothyroid, omohyoid).
 - Sternomastoid muscle.
- Above the upper border of thyroid cartilage:
 - Styloid process and attached structures.
 - Posterior belly of Digastric m.
 - Parotid gland.

DEEP RELATIONS:

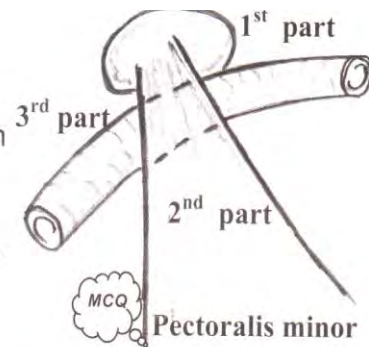
- MCQ = Transverse processes of all cervical vertebrae and the covering prevertebral muscles & fascia.
- Inferior thyroid artery: crosses deep to it at C6 (on both sides).
- Thoracic duct: crosses deep to it at C7 (on left side).



Axillary Artery

Begins: at the outer border of 1st rib as a continuation of subclavian artery.

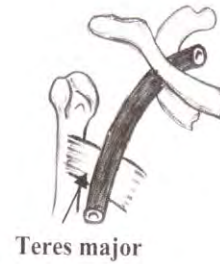Ends: at the lower border of the teres major muscle as brachial artery.



Pectoralis minor muscle divides the axillary artery into 3 parts:

A-1st Part:

- Lies above the pectoralis minor muscle.
- **Relation** : (see diagram)
- **Branches**: superior thoracic artery.



B-2nd Part:

- Lies behind pectoralis minor.
- **Relation**: (see diagram)
- **Branches**:
 - 1- Thoracoacromial artery (pierce clavipectoral fascia),
 - 2- Lateral thoracic artery (supplies ♀ breast).

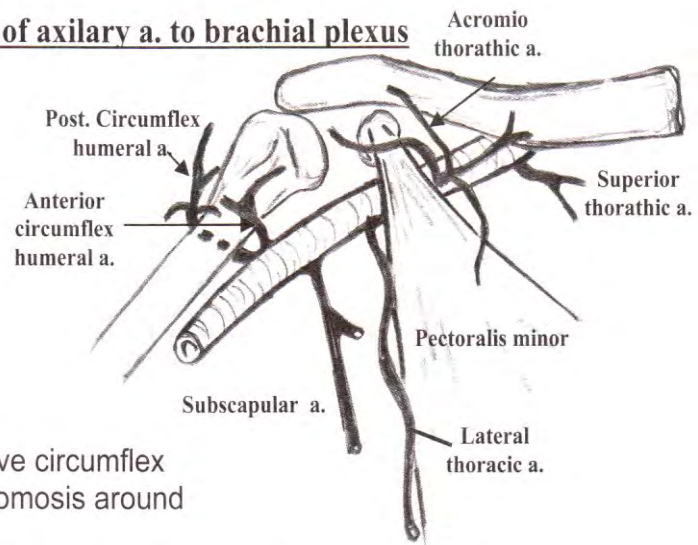
C-3rd Part:

Relations of axillary a. to brachial plexus

- Lies below pectoralis minor
- Lies medial to the short head of biceps & coracobrachialis.
- **Relation**: (see diagram)

Branches:

- Subscapular: give circumflex scapular (anastomosis around scapula).
- Posterior circumflex humeral: around the surgical neck.
- Anterior circumflex humeral: around the surgical neck & gives branches to the shoulder joint.



Surgical Importance:

Exposure:

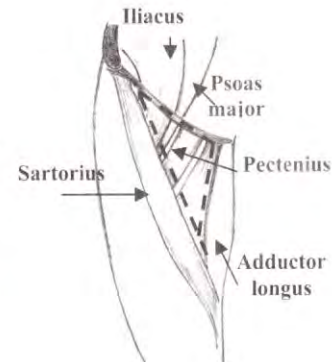
- The incision used to expose the subclavian artery in the neck can be extended across the clavicle into the deltopectoral groove.
- A subclavicular incision 1 cm below the clavicle (started at the junction of the medial 1/4 with the outer 3/4 of the clavicle & extended for 6 cm laterally).

Femoral Triangle (Scarpa's Triangle)

MCO It is a **subfascial space** occupying the front of the **upper 1/3** of the thigh just below the inguinal ligament.

BOUNDARIES:

- **Laterally:** Medial border of Sartorius.
- **Medially:** Medial border of adductor longus (so the muscle also shares in the floor)
- **Base:** Poupart's ligament (inguinal ligament).
- **Apex:** meeting of sartorius & adductor longus (beginning of Hunter's canal)

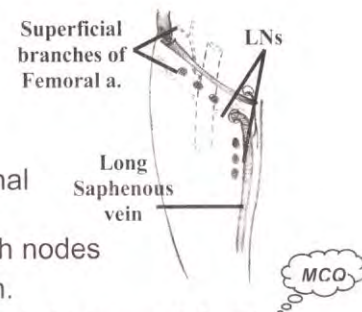


FLOOR:

From medial to lateral: → adductor longus, pectineus, psoas major & iliacus muscle

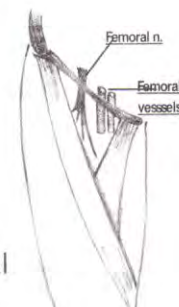
ROOF:

1. Skin.
2. **Superficial fascia** consisting of fatty layer & membranous layer just a fingerbreadth below inguinal ligament
3. In between there are:
 - superficial branches of femoral a.: (superficial epigastric, superficial external pudendal & superficial circumflex iliac)
 - The "T" shaped superficial inguinal lymph nodes
 - Great saphenous v. & the ilio-inguinal n.
4. **Deep fascia** containing the **saphenous opening** (which is a defect in the fascia covered by cribriform fascia)



CONTENTS:

- 1) **Femoral artery:** & its branches; profunda femoris
- 2) & deep external pudendal
- 3) **Femoral vein:** & its tributaries
- 4) **Femoral sheath:** surrounding the upper 4 cm of femoral vessels
- 5) **Femoral nerve:** (outside the sheath), but femoral branch of genitofemoral n. is inside the sheath
- 6) **Deep inguinal LNs**



N.B: At the apex: structures are arranged from anterior to posterior as: Femoral artery, femoral vein, profunda femoris vein & profunda femoris artery.

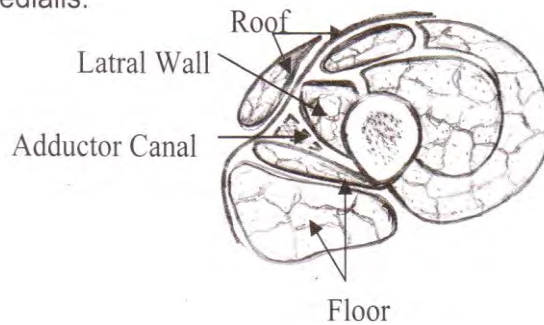
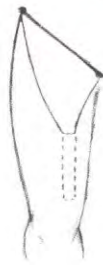Hunter's Canal (Adductor or Subsartorial Canal)

SITE: middle 1/3 of the thigh. It begins at the apex of femoral triangle & ends at the opening in adductor magnus m.

MCQ

BOUNDARIES

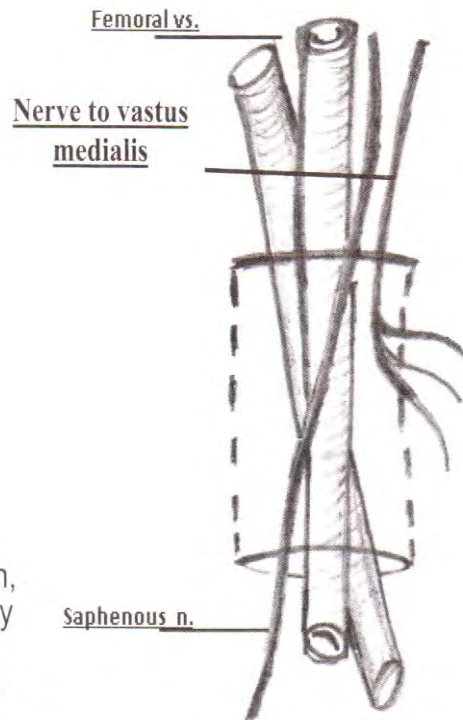
- **Roof:** a strong fibrous membrane on which lies the sartorius m.
- **Floor:** adductor longus & magnus muscles
- **Lateral Wall:** vastus medialis.



CONTENTS

1. **Femoral vessels.** The vein at first is behind the artery then lateral to it
2. **Descending genicular a.** → From femoral a. (anastomtica magna)
3. **Nerve to Vastus- medialis** → Lateral to the vessels
4. **Saphenous nerve** → Crosses the vessels from lateral to medial side.

MCQ



SURGICAL IMPORTANCE:

To ↓ the bleeding in above knee amputation, we ligate the femoral vessels in the canal by dividing the Sartorius & its fascia. However, if there is arteriosclerosis there is no need for ligation.

The Femoral Artery

MCQ **Begins:** As the continuation of external iliac artery behind the midinguinal point (Midway between ASIS & symphysis pubis)

MCQ **Ends:** by becoming the popliteal artery by passing through an opening in the adductor magnus between its 2 insertions (10cm above knee joint)

Surface Anatomy: (with the thigh flexed, abducted & laterally rotated)


It corresponds to the upper $\frac{2}{3}$ of a line drawn from the mid-inguinal point to the adductor tubercle

Branches:

MCQ It is the main artery of the LL & also supplies part of the ant abd wall

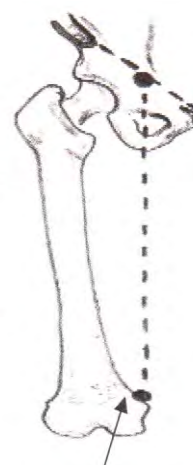
A) 3 Superficial

- MCQ** • Superficial external pudendal artery.
- Superficial epigastric artery.
- Superficial circumflex iliac artery.

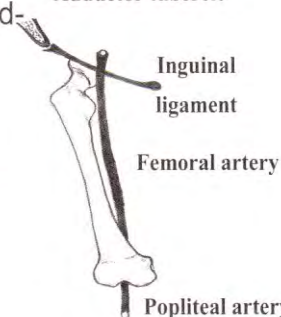


B) 3 Deep

- MCQ** • Deep external pudendal artery.
- MCQ** • **Deep femoral artery (profunda femoris artery):**
 - It arises from the posterolateral aspect of the common femoral artery 2-4 cm distal to the inguinal ligament
 - It is the main supply to medial & posterior compartments of the thigh.
 - It gives 6 branches:
 - Lateral femoral circumflex artery
 - Medial femoral circumflex artery
 - 4 perforating branches
- MCQ** • **Descending genicular artery (anastomotica magna)**
 - Enters into collateral circulation around the knee



Adductor tubercle



Inguinal ligament

Femoral artery

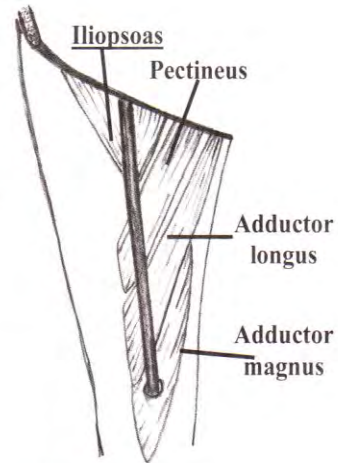
Popliteal artery

Relations:

- **Common Femoral artery (above origin of profunda femoris a)**

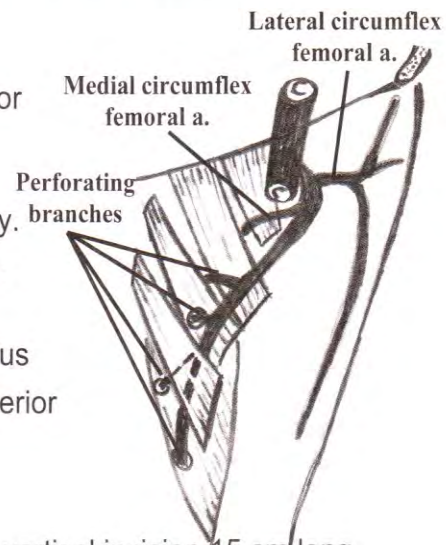
Lies in the lateral compartment of the femoral sheath. So

- **Medially** is the femoral vein
- **Laterally** is the femoral branch of the genitofemoral nerve & femoral nerve
- **Posteriorly** it lies on Psoas major & Pectineus muscle.



- **Superficial Femoral artery (below origin of profunda femoris a)**

- Passes first in the femoral triangle.
 - Deep to it are the profunda vessels, pectineus & adductor longus muscles.
 - The femoral vein is first medial then behind the artery.
- Then the artery passes in the Hunter's canal
 - It lies posterior to the Sartorius
 - The femoral vein is first posterior then lateral to it.



Exposure

- The femoral vessels are best exposed by a vertical incision 15 cm long and centred over the midfemoral point
- The deep fascia of the leg is incised, and the artery is found lying lateral to the common femoral vein
- The contents of the inguinal canal are protected by upward retraction

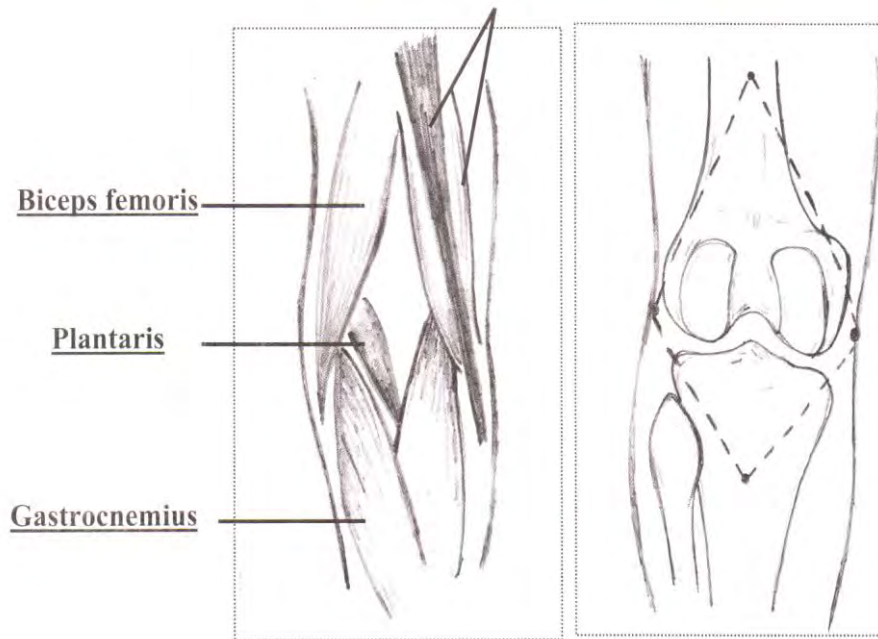
Popliteal fossa

BOUNDARIES:

MCO

1. **Upper lateral:** biceps femoris.
2. **Upper medial:** semitendinosus & semimembranosus muscles supplemented by the sartorius, gracilis & adductor magnus.
3. **Lower lateral:** lateral head of gastrocnemius supplemented by the plantaris muscle.
4. **Lower medial:** medial head of gastrocnemius.

Semitendinous & semimembranosus

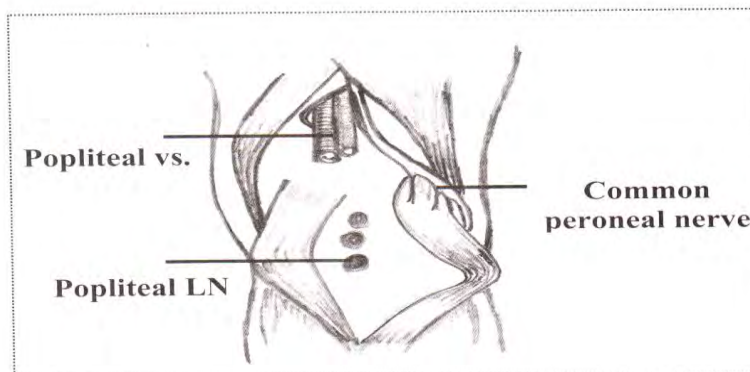


CONTENTS:

MCO

1. Lateral popliteal nerve (**common peroneal nerve**).
2. Medial popliteal nerve (**Tibial nerve**).
3. Popliteal artery.
4. Popliteal vein.
5. Termination of the **posterior cutaneous nerve of the thigh**.
6. Popliteal lymph nodes.

All these structures are embedded in a variable amount of fat.



ROOF:

The roof of the fossa is formed by

- Skin,
- Superficial fascia containing:
 - The upper part of the short saphenous vein
 - branches of the posterior cutaneous nerve of the thigh
- The deep fascia of the roof is called the popliteal fascia & is a downward extension of the fascia lata. *It is pierced by saphenous vein*

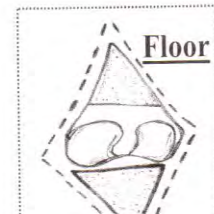
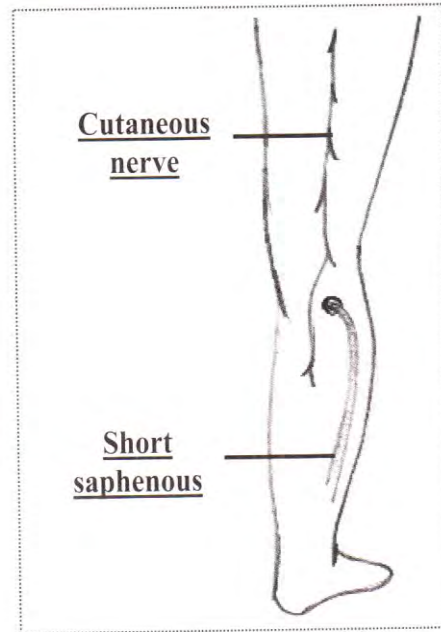
MCQ

It is pierced by saphenous vein

FLOOR:

MCQ

1. **Upper part:** popliteal surface of femur.
2. **Middle part:** back of the capsule of the knee joint.
3. **Lower part:** fascia covering the popliteus muscle. The lower limit of the fossa is the distal border of the popliteus muscle.

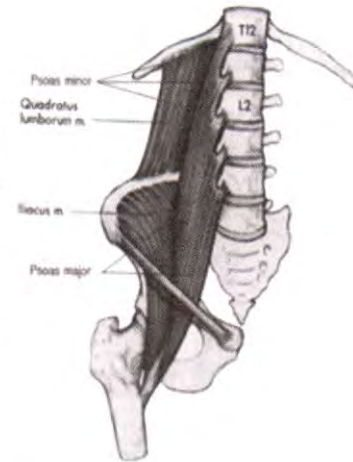


Psoas Major

ORIGIN:

MCO

- 1) Front of the transverse processes of all lumbar vertebrae.
- 2) By 5 digitations, each of which arises from the sides of the bodies of each 2 adjacent lumbar vertebrae and the intervertebral discs in between.
- 3) From tendinous arches attached to the sides of the lumbar vertebrae. These arches bridge over the lumbar arteries.



INSERTION:

MCO

- The muscle descends medial to iliacus m & continues downwards to enter the front of the thigh **behind inguinal ligament above superior pubic ramus.**
- Its tendon receives fibers of the iliacus ms & is inserted into the **lesser trochanter of the femur.**

NERVE SUPPLY:

Branches from the lumbar plexus (L 1, 2, 3).

ACTION:

MCO

- 1) It flexes the thigh and rotates it medially. But in fracture of the neck of femur, the muscle rotates the thigh laterally.
- 2) Acting from below, the muscle bends the trunk forwards.

PSOAS FASCIA

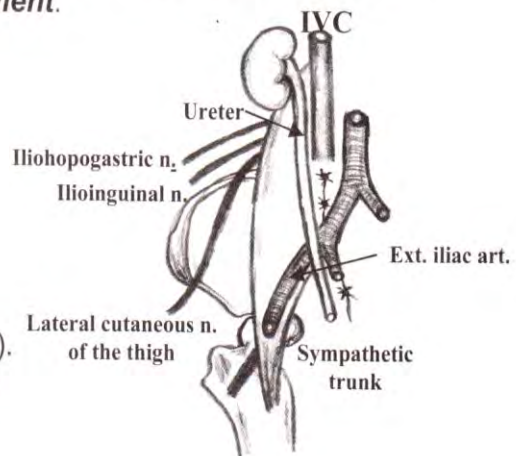
The Psoas Major is enveloped by the psoas fascia, which is thickened in its upper part to form the **medial arcuate ligament.**

RELATIONS OF PSOAS MAJOR:

• Anteriorly:

Common for Lt. and Rt. muscles

- 1) Kidney and its renal vessels.
- 2) Ureter and renal pelvis.
- 3) Gonadal vessels.
- 4) Genitofemoral nerve.
- 5) Psoas minor (in 60% of population).
- 6) End of the ileum (on the right) and descending colon (on the left).
- 7) Inguinal ligament.



Specific for Lt. muscle

4th part of duodenum, root of mesentery and superior mesenteric vessels.

Specific for Rt. muscle

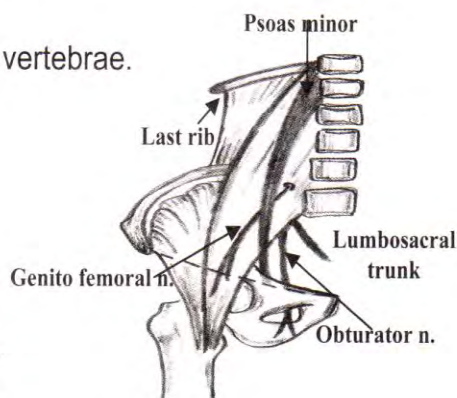
IVC, 2nd and 3rd parts of duodenum

• **Posteriorly:**

1. Transverse processes of lumbar vertebrae.
2. Superior pubic rami.

• **Laterally:**

1. Quadratus lumborum (above).
2. Iliacus (below).
3. Iliohypogastric nerve.
4. Ilioinguinal nerve.
5. Lateral cutaneous nerve of thigh.
6. Femoral nerve (the lower most).



Medially:

- 1) Sympathetic trunk (along its medial margin).
- 2) External iliac vessels (at the brim of the pelvis).
- 3) 2 nerves: obturator nerve and lumbosacral trunk.

POINTS OF SURGICAL IMPORTANCE:

a. Psoas sign:

- In acute appendicitis, there is spasm of psoas major muscle → flexion deformity
- Hyperextension of the rib leads to abdominal pain (psoas sign)

b. Psoas Abscess:

- Produces cross fluctuation (DD: mass in the rt. iliac fossa & mass in the femoral triangle)

c. Obliterated Psoas Shadow in X-Ray film:

- Rupture spleen
- Perinephric abscess

d. In fracture neck of the femur the muscle rotates the thigh laterally (not medially)

Ulnar Nerve

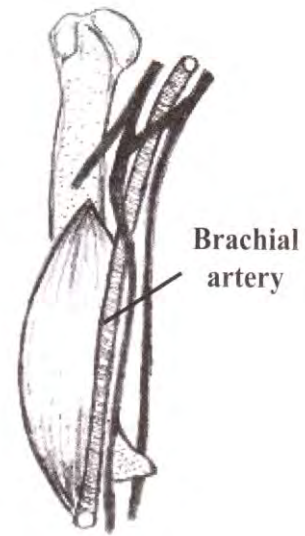
COURSE & RELATIONS:

In the axilla & arm :

- It arises as the **termination of medial cord** of brachial plexus between 3rd part of axillary artery & axillary vein.
- It descends medial to brachial artery till the insertion of coracobrachialis where it deviates medially & downwards to pierce the medial intermuscular septum, to **reach the posterior compartment of the arm**

MCO

MCO



In the forearm:

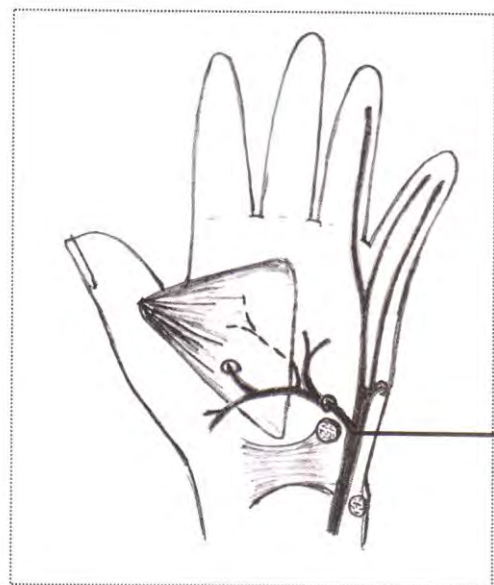
MCO

- It enters the forearm by passing **behind the medial epicondyle**
- It passes between the 2 heads of **flexor carpi ulnaris**, & descends along the medial side of forearm **between flexor carpi ulnaris & flexor digitorum profundus**
- Continues downwards **superficial** to the flexor retinaculum.

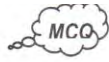

In the hand :

- Terminates just lateral to pisiform bone by dividing into superficial & deep branches.



Termination of the ulnar n

BRANCHES:**In the forearm:**

- **Motor:** to supply flexor carpi ulnaris + medial ½ of flexor digitorum profundus.
- **Sensory:**
 - medial ⅓ of the palm & medial ⅓ of the back of the hand
 - back of the medial 1½ fingers

In the hand:

- **Motor:**
 - Adductor pollicis.
 - 3 muscles of the hypothenar eminence.
 - Palmaris brevis muscle.
 - 3rd & 4th lumbricals.
 - All interosseous muscles (palmar & dorsal).

i.e., ulnar nerve supplies all intrinsic muscles of the hand except the 3 thenar muscles + 1st & 2nd lumbricals
- **Sensory:** to the Palmar surface of the medial 1 ½ finger

SURGICAL IMPORTANCE (ULNAR NERVE INJURY):**At wrist:**

- **Motor:**
 - Wasting of hypothenar eminence.
 - Partial claw hand.
 - +ve Froment's test.
 - +ve card test + loss of abduction.
 - Guttering between metacarpal bones.
- **Sensory:** sensory loss over:
 - Medial ⅓ of the palm.
 - Medial 1½ fingers.

At elbow: As above + loss of ulnar deviation + ulnar paradox

Median Nerve

COURSE & RELATIONS:

MCQ

In the axilla & arm:

- It arises in the axilla by 2 branches from medial cord & lateral cord of brachial plexus (C5, C6, 7, 8 & T1).
- It crosses *in front* of the brachial artery *from lateral to medial*.
- It lies medial to biceps, anterior to brachialis & triceps

In the forearm:

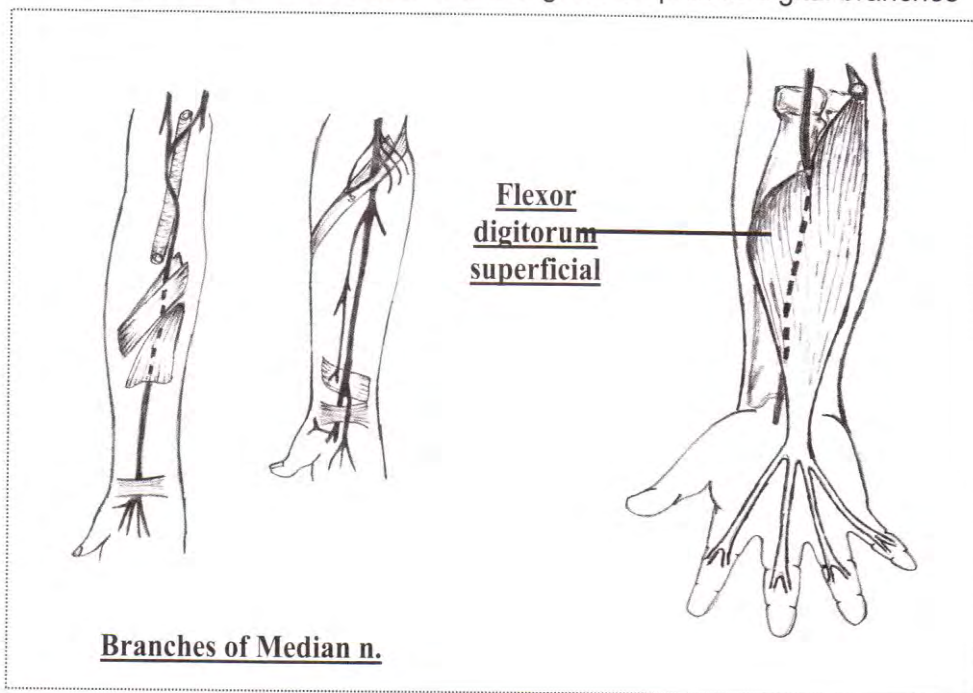
- In the cubital fossa, it passes:
 1. medial to the brachial artery.
 2. in front of the insertion of brachialis
- It leaves the cubital fossa by passing between the 2 heads of *pronator teres*.
- Passes *deep to flexor digitorum superficialis* where it is adherent to its undersurface & runs in front of flexor digitorum profundus.
- About 5 cm above the wrist: lies in the interval between flexor carpi radialis (laterally) & palmaris longus (medially).

MCQ

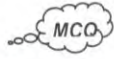In the hand:

MCQ

- The nerve enters the carpal tunnel immediately **under cover of the flexor retinaculum**.
- **It terminates** Just distal to the flexor retinaculum, by dividing into lateral & medial divisions each of which gives off palmar digital branches



BRANCHES:

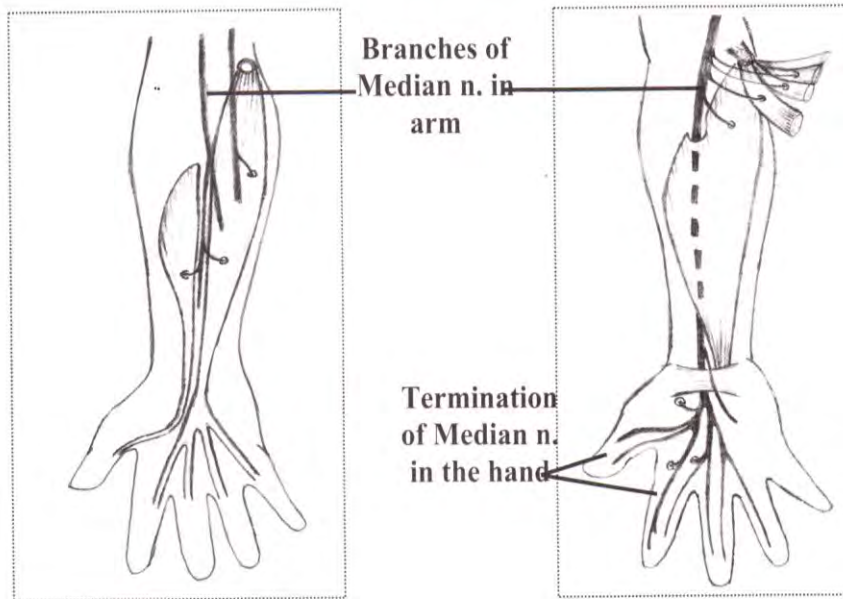


In the forearm:

- **Motor:** to all flexors of the forearm except flexor carpi ulnaris + 1/2 flexor digitorum profundus
- **Sensory** (Palmar cutaneous branch): arises about 5 cm above the flexor retinaculum then passes in front of it to supply skin of the lateral 2/3 of the palm (but not the digits)

In the hand:

- **Motor:** to the 3 thenar muscles (flexor pollicis brevis, abductor pollicis brevis & opponens pollicis) + lumbricals (1st & 2nd)
- **Sensory** (palmar digital branches): to the palmar surface of the lateral 3 1/2 fingers



SURGICAL IMPORTANCE (MEDIAN NERVE INJURY):

At wrist:

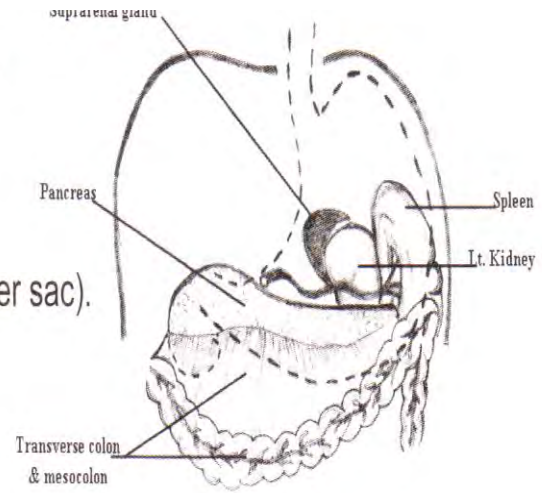
- **Motor:**
 - Waisting of thenar eminence
 - Loss of apposition
 - Weakness of abduction of the thumb
- **Sensory:** sensory loss over
 - Lateral 2/3 of palmar surface of the hand
 - Lateral 3 1/2 fingers (palmar surface)
- **Deformity:** Ape hand deformity

At elbow: As above + ulnar deviation + positive clasp test

MCQ

B- Posterior: (The Stomach Bed)

- 1- Lt. crus of the diaphragm.
- 2- Lt. suprarenal gland .
- 3- Lt. kidney.
- 4- Spleen (separated by greater sac).
- 5- Splenic a.
- 6- Body of pancreas.
- 7- Transverse mesocolon.
- 8- Transverse colon.



N.B. All are separated from the stomach by lesser sac except spleen by greater sac

The Kidney

Embryology: fusion of mesonephric with metanephric ducts.



- Secreting part: from metanephros
- Collecting system: from ureteric bud of mesonephric duct

Points of Surgical Importance:

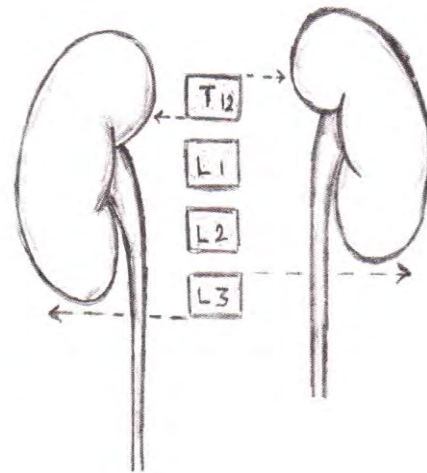
- failure of fusion of mesonephric with metanephric ducts → polycystic kidney
- in non rotated kidney, the hilum is directed anteriorly

Anatomy:

SIZE: 12 X 6 X 3 cm

POSITION:

- The kidney is retroperitoneal occupying the loins
- They are in the paravertebral gutter.
- The Rt. kidney is lower than the Lt. by 0.5 inch because of the pressure of the liver on the Rt. side.



	<u>Rt. Kidney</u>	<u>Lt. kidney</u>
1. Upper pole	Lower border of T ₁₂	Upper border of T ₁₂
2. Lower pole	lower border of L ₃	Upper border of L ₃

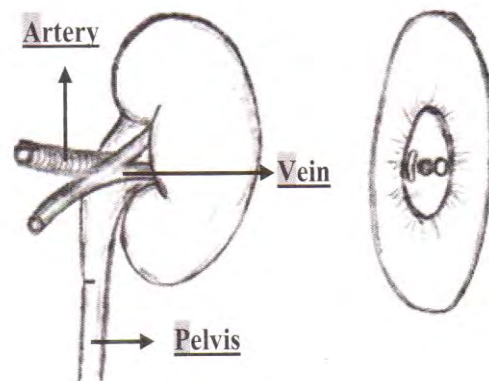


PEDICLE: In the hilum we have (VAP)

- Renal vein → anterior
- Renal artery → middle
- Pelvis of the ureter → posterior

Surgical Importance:

In nephrolithotomy we open the posterior surface but at radical nephrectomy we open the anterior surface

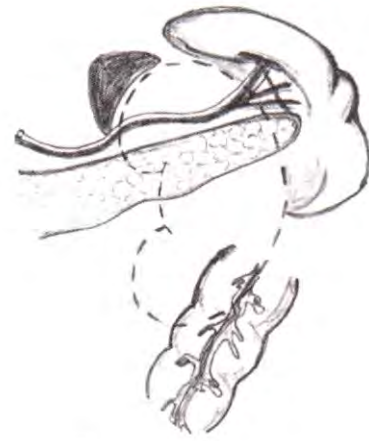

RELATIONS



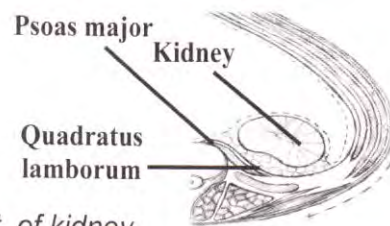
A) Anterior Relations

- Left Kidney (stomach bed)
 - Suprarenal: above & medial
 - Spleen: above & lat.
 - Stomach: between suprarenal, spleen & splenic a.
 - Pancreas & splenic vessels
 - Splenic flexure: below & lateral
 - Small intestine: below & medial
- Right Kidney
 - Suprarenal: above & medial
 - Second part of duodenum: in front of hilum.
 - Rt. colic flexure: below & lateral
 - Small intestine: below & medial
 - Rt. lobe of liver: above & lateral



B) Posterior Relations

- Both Rt. & Lt. Kidney.
 - 4 Muscles
 - 1) Diaphragm: superior
 - 2) Psoas major: lower medial
 - 3) Quadratus lumborum: lower intermediate
 - 4) Transversus abdominis: lower lateral.



4 structures separating muscles from the post. of kidney

- 1) Subcostal vessels & nerve.
- 2) 11th & 12th ribs in Lt. kidney (only 12th rib in Rt.)
- 3) Iliohypogastric nerve
- 4) Ilioinguinal nerve

BLOOD SUPPLY OF THE KIDNEY:



- 1) Arterial supply: renal a. (branch of abdominal Aorta at L1/L2)
 - Rt renal artery is longer than Lt renal a. & it passes behind IVC
 - Blood supply to the kidney is segmental → end arteries
 - Accessory renal arteries
 - are of common occurrence
 - usually arise from the abdominal aorta.
 - can cause ureteric obstruction
 - Ligation → infarction of the part supplied by them
- 2) Venous drainage: renal vein (drains into IVC)

CAPSULE OF THE KIDNEY:

A-Fascia Of Zukercandle (Gerota)(Perirenal capsule)

The fascia transversalis reaching the kidney splits into:

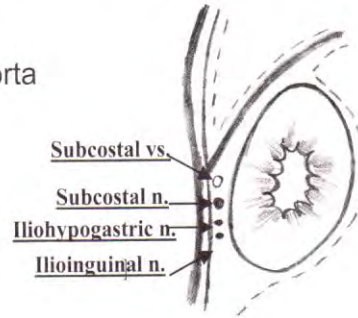
- Anterior layer → attached to aorta
- Posterior layers → attached to vertebral fascia

The two layers

- Above → fuse above
- Below → no fusion



N.B: Gerota fascia encloses the kidney BUT NOT the adrenal gland.



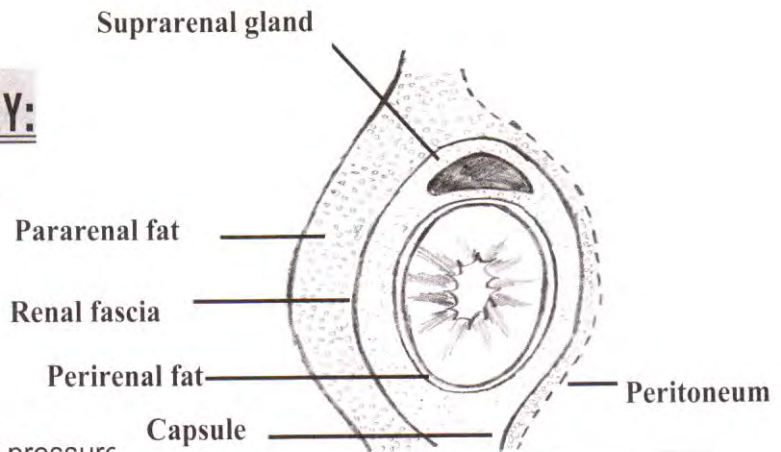
B-Fibrous Capsule

C-Perinephric fat

Surgical Importance no fusion from below → Kidney is liable to ptosis.

STABILITY OF THE KIDNEY:

- Its position in the paravertebral gutter
- Its fascial & fatty capsules
- The renal vessels connecting the kidney to Aorta & IVC
- The intra-abdominal pressure

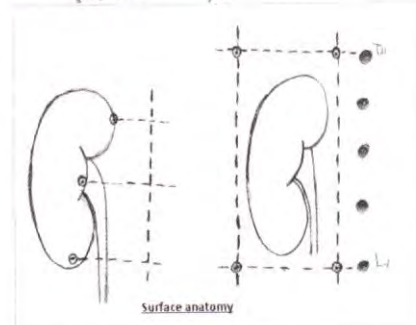


SURFACE ANATOMY OF THE KIDNEY:

A. Posterior surface markings of the kidney:

bounded by 4 lines (**Morris' parallelogram**):

- 2 vertical lines: 3, 9 cm from median plane
- 2 horizontal lines: at level of T₁₁ and L₃



B. Anterior surface marking of the kidney:

	Right kidney	Left kidney
Upper end	11 th space	11 th rib
Lower end	5 cm above iliac crest	6.5 cm above iliac crest

Urinary Bladder

SITE:

- At birth: it lies in the abdominal cavity (Pelviabdominal organ)
- In adult: it occupies the anterior part of the pelvis (Pelvic organ)

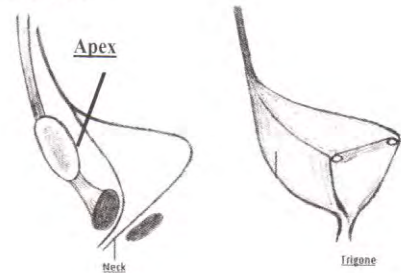
4 ANGLES:

- Apex:
 - attached to median umbilical ligament.
 - If remains patent, it may cause:
 - Urachal (sinus, fistula, cyst)
 - Congenital diverticulum
- Neck: Lying on prostate (♂) or pelvic fascia (♀), it gives the urethra
 Surrounded by smooth muscle fibers constituting the sphincter vesicae
- 2 posterosuperior angles: receiving the 2 ureters

4 SURFACES: Superior, posterior & 2 inferolateral

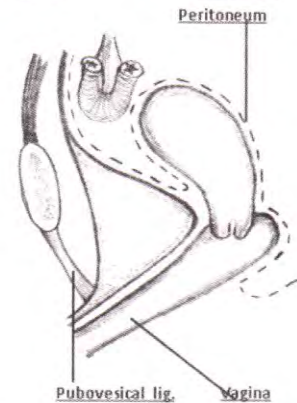
PERITONEAL COVERING: MCQ

- Male: superior surface & upper of base.
- Female: superior surface ONLY.



Angles

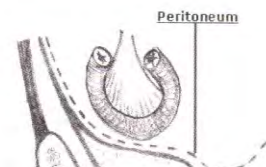Surfaces



Peritoneum

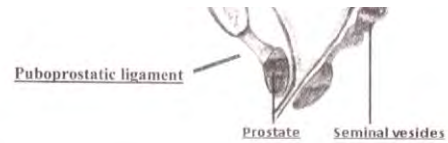
RELATIONS

- Anterior:
 - Male: puboprostatic ligament.
 - Female: pubovesical ligament.
 1. They fix bladder in pelvis.
 2. They are present in Cave Of Retzius "Retropubic space"
- Lateral: Lateral wall of the pelvis.
- Superior:
 - Male: intestine
 - Female: the uterus & intestine



Peritoneum

CAVITY OF THE BLADDER



Trigone:

- Triangular part of the base between the 2 openings of the ureter & the opening of the urethra
- Characters:

1. No rugae
2. Pink (rich blood supply)

Surgical Importance (if stone → hematuria)

3. No submucosa

Surgical Importance: → No bilharziasis → No Egyptian cancer

4. It is richly supplied by nerves

Surgical Importance: It is more sensitive to pain.

Ureteric orifices:

- They lie at the posterolateral angles of the trigone
- The 2 orifices are separated from each other by a transverse ridge called the interureteric crest

Internal urethral orifice:

- It is placed at the lowest part of the bladder.
- It is surrounded by an involuntary non-striated muscle forming the sphincter vesicae.

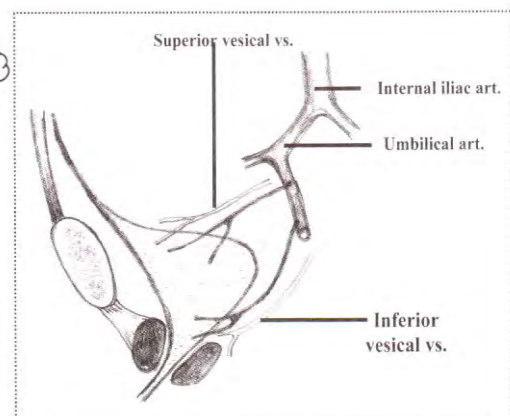
Intramural part of the ureter:

- The lowermost part of the ureter passes obliquely through the wall of the bladder; this part is called the intramural part.

Surgical Importance: The oblique course of the intramural part is a factor in preventing regurgitation of urine into the ureter when the bladder is distended.

BLOOD SUPPLY:

- 1) Vesical arteries: From internal iliac a.
- 2) Vesical veins: → internal iliac vein.
It is connected with vesal, ureteric, prostatic & hemorrhoidal plexus of veins.



IDENTIFICATION DURING OPERATION

- Brownish network of muscles
- Bluish network of venous plexus
- Fill it with saline → Balloons.
- Stone

Prostate

NATURE: it is a fibromuscular **exocrine glandular** organ.

MCQ

(Senile enlarged prostate is an fibromyoadenoma)

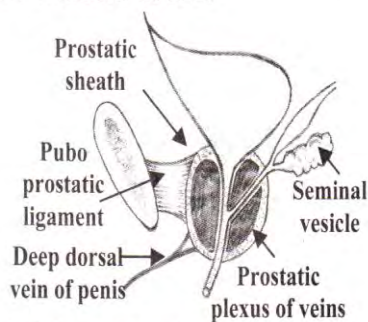
SITE: present in males, below the bladder neck & is behind symphysis pubis.

STRUCTURE: It is **partly glandular** consisting of numerous follicles, & **partly muscular** consisting of non-striated muscle fibres.

SHAPE:

MCQ

- It resembles an **inverted cone** with
 - its base directed upwards
 - its apex directed downwards.
 - 4 surfaces : posterior, anterior & 2 inferolateral.



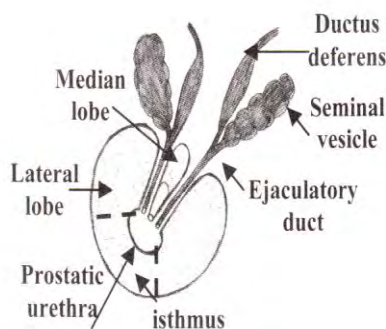
- It weighs 8 gm & measures 4 cm from side to side at the base, & 3 cm from base to apex.

CAPSULES:

- It has a firm fibrous capsule which is adherent to the prostate substance
- **Inner** → true fibromuscular capsule.
- **Outer** → fascia capsule (**fascia of Denonvillier**), which delays direct spread of cancer between rectum & prostate.

POSITION:

- It **surrounds** the prostatic urethra.
- It **lies behind** the lower border of symphysis pubis, & in front of the lower part of rectum.
- Its level **lies** about 4 cm from the anal orifice → & thus can be palpated by PR examination.



LOBES OF THE PROSTATE:

- By means of prostatic urethra to ejaculatory ducts , the prostate is divided into 5 lobes :
 1. Anterior lobe (isthmus) : in front of prostatic urethra , consists of fibromuscular tissue with little glandular tissue
 2. , 3. Right and Left Latral lobes : one on each side of the prostatic urethra , they are the usual sites for senile enlarged prostate
 4. Posterior lobe : behind prostatic urethra but below the 2 ejaculatory ducts , It is the usual site for cancer prostate .
 5. Median lobe :
 - Between the upper part of the prostatic urethra and the 2 ejaculatory ducts
 - After Middle age , it produces " uvula vesicae " in the lower part of the bladder trigone .
 - It is also a common site for senile enlarged prostate.

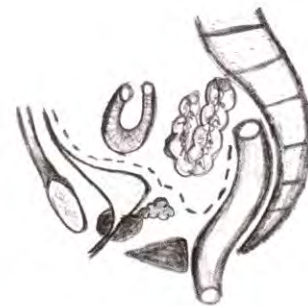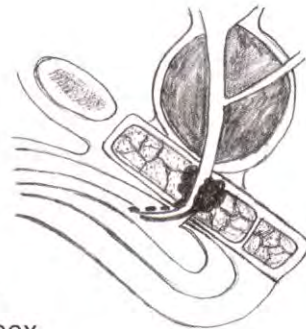NB:



- The median lobe of the prostate contains more glandular material than the other lobes.
- During P/R: only Posterior parts of lateral lobes & Post lobe can be palpated

RELATIONS:

- **Base:**
 - Surrounds the neck of the bladder
 - Pierced by the urethra.
- **Apex:**
 - Lies on the roof of the deep perineal pouch
 - The urethra emerges from the anterior surface of the prostate just above its apex.
- **Posterior surface:**
 - Lies in direct contact with the lower part of the rectum
 - It can be palpated by PR examination in the living.
- **Anterior surface:**
 - lies about 2 cm behind the pubic symphysis
 - It is connected to the pubic bones by the puboprostatic ligaments.
- **Inferolateral surfaces** (one on each side):
 - Rest on the anterior free borders of the 2 levator ani.
 - The most anterior fibres of the muscles sweep backwards on each side of the prostate to be inserted into the perineal body; these fibres form what is called the levator prostatae.



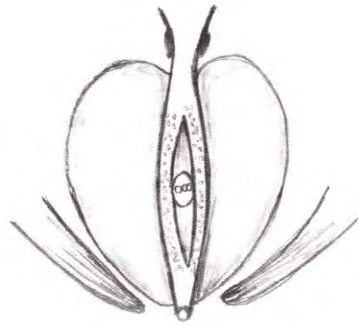
STRUCTURES WITHIN THE PROSTATE:

1) **Prostatic urethra:** traverses the prostate from the base to the apex along the junction of the anterior $\frac{1}{3}$ with the posterior $\frac{2}{3}$ of the gland.

2) **Ejaculatory ducts:** the 2 ducts run downwards & forwards one on each side of the median plane to open into the back of the **prostatic urethra**.

MCQ

3) **Prostatic utricle:** extends upwards & backwards from the prostatic urethra into the median lobe.



PR EXAMINATION:

The normal prostate is:

Smooth

Soft

Slippery rectal mucosa

Sulci can be felt

Symmetrical

BLOOD SUPPLY:

A) **Arterial** → inferior vesical & middle rectal

B) **Venous**

- Prostatic venous plexus of Santorini which lies between the true & the false capsule.
- These are thin walled valveless veins
- It receives the deep dorsal vein of the penis
- It communicates with vesical venous plexus
- It drains into the internal iliac v. which communicates with int. vertebral venous plexus (valveless lateral sacral veins).

MCQ

SURGICAL IMPORTANCE:

Cancer prostate reaches vertebral column rapidly through valveless veins of BATESON

Good luck

Dr. Wael Metwaly